Essentials of Sonographic Image Interpretation

Pre-Lecture Worksheet | Student Resource

Name: _____ Date: _____

Review of Sonographic Vocabulary

Match each key term with the correct definition.

KEY TERMS

- [ ] 1. echogenicity
- [ ] 2. anechoic
- [ ] 3. hyperechoic
- [ ] 4. hypoechoic
- [ ] 5. isoechoic
- [ ] 6. focal
- [ ] 7. diffuse
- [ ] 8. cystic
- [ ] 9. solid
- [ ] 10. complex

DEFINITIONS

A. echo-producing structure that may have iso-, hypo-, or mixed appearance

B. discrete, well-marginated area of differing echogenicity

C. increased echo level compared with adjacent tissue

D. the same echo level as adjacent tissue

E. the ability of a structure to produce echoes

F. structure containing both solid and cystic components

G. broadly distributed area of differing echogenicity

H. decreased echo level compared with adjacent tissue

I. absence of echoes within a structure

J. anechoic, fluid-filled structure with posterior acoustic enhancement

Essentials of Sonographic Image Interpretation

Pre-Lecture Worksheet | Student Resource

Image Labeling

Choose all sonographic characteristics that apply to the circled area.

IMAGE 1

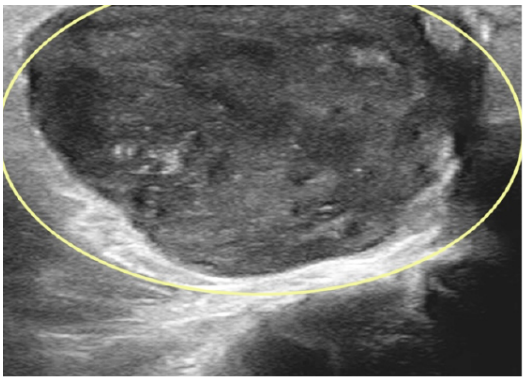

- ☐ anechoic
- ☐ poorly marginated
- ☐ smoothly marginated
- ☐ homogeneous
- ☐ heterogeneous
- ☐ cystic
- ☐ solid

IMAGE 2



- ☐ anechoic
- ☐ poorly marginated
- ☐ smoothly marginated
- ☐ homogeneous
- ☐ heterogeneous
- ☐ cystic
- ☐ solid

Essentials of Sonographic Image Interpretation

Pre-Lecture Worksheet | Student Resource

Image Labeling continued

Choose all sonographic characteristics that apply to the circled area.

IMAGE 3

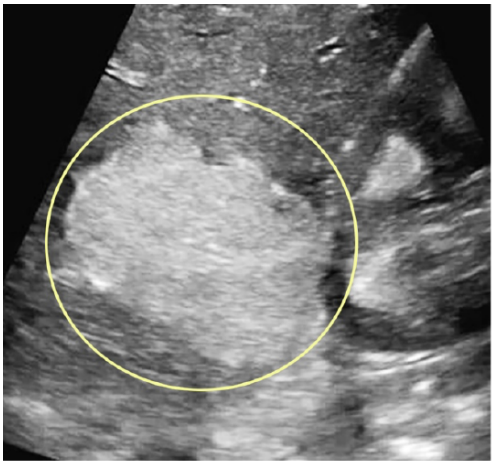

- ☐ hypoechoic
- ☐ hyperechoic
- ☐ smoothly marginated
- ☐ irregularly marginated
- ☐ complex
- ☐ cystic
- ☐ solid

IMAGE 4



- ☐ hypoechoic
- ☐ homogeneous
- ☐ heterogeneous
- ☐ smoothly marginated
- ☐ irregularly marginated
- ☐ cystic
- ☐ complex

Essentials of Sonographic Image Interpretation

Pre-Lecture Worksheet | Student Resource

Image Labeling continued

Choose all sonographic characteristics that apply to the circled area.

IMAGE 5

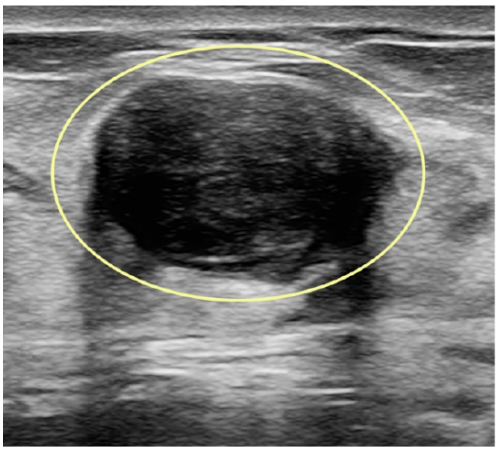

- ☐ hypoechoic
- ☐ hyperechoic
- ☐ smoothly marginated
- ☐ irregularly marginated
- ☐ cystic
- ☐ solid
- ☐ complex

IMAGE 6



- ☐ hypoechoic
- ☐ hyperechoic
- ☐ smoothly marginated
- ☐ irregularly marginated
- ☐ cystic
- ☐ solid
- ☐ complex

Essentials of Sonographic Image Interpretation

Pre-Lecture Worksheet | Student Resource

Fill in the Blanks

Complete each statement using terminology from the white paper.

1. Assessment of sonographic morphology consists of an analysis of:

2. Assessment of acoustic physical interactions consists of an analysis of:

3. Sonographic structures are generally classified as:

4. _____ refers to the overall appearance of an anatomic organ or pathologic structure.

5. The global sonographic appearance of a structure consists of its external boundaries and shape, called _____, and its interior architecture, called _____.

6. The _____ of a structure refers to its shape, outline, or boundaries.

7. Contour boundaries can be described as:

8. The relative amplitude of the internal echo pattern is called _____.

9. A mass that is more echogenic than surrounding tissue is called _____.

10. A mass that is less echogenic than surrounding tissue is called _____.

Essentials of Sonographic Image Interpretation

Pre-Lecture Worksheet | Student Resource

Fill in the Blanks continued

Complete each statement using terminology from the white paper.

11. A mass that has the same echogenicity as surrounding tissue is called _____.

12. A synonym for hypoechoic is _____.

13. A structure that contains no internal echoes is called _____.

14. A synonym for anechoic is _____.

15. A structure that contains a mix of hyperechoic and hypoechoic areas is described as _____.

16. A structure that appears uniformly echogenic is described as _____.

17. Alterations distributed broadly and relatively evenly throughout a structure are described as _____.

18. A localized, discrete region that differs in echogenicity or architecture from surrounding tissue is referred to as _____.

19. _____ is the decrease in amplitude and intensity of a sound wave as it is transmitted through a medium.

20. Excessive loss of acoustic energy through a tissue bed is described as highly attenuative or _____.

21. The most notable appearance of a hyperattenuating structure is that it appears relatively _____ on a grayscale image.

Essentials of Sonographic Image Interpretation

Pre-Lecture Worksheet | Student Resource

Fill in the Blanks continued

Complete each statement using terminology from the white paper.

22. An exaggerated manifestation of hyperattenuation is called _____.

23. The most common source of posterior acoustic shadowing is _____ or another highly attenuative material.

24. _____ is the physical phenomenon opposite to posterior acoustic shadowing.

25. Posterior acoustic enhancement is strong evidence of a _____.

26. _____ are a variant of conventional reverberation artifacts arising from small, highly reflective interfaces too closely spaced to be resolved individually.

27. _____ artifacts result when an acoustic wavefront encounters small gas bubbles trapped within fluid.

28. Fluid-filled structures are called _____.

29. Classic sonographic characteristics of a simple cystic structure include:

30. Echoes within solid structures typically result from _____.

31. _____ are generally described as containing both cystic and solid elements.